

ORIGINAL ARTICLE

THE INTERSECTION OF TUBERCULOSIS AND CARDIOVASCULAR DISEASE:
A SYSTEMATIC REVIEWAzene Dessie Mengistu, MD^{1*}

ABSTRACT

Background: Tuberculosis is one of the oldest infectious diseases known to affect every organ and tissue of the human body and the heart is no exception. However, cardiac manifestations of tuberculosis are not given enough attention in clinical practice in developing countries, where intersection of the two epidemics are observed.

Objectives: The goal of this clinical review is to restore awareness among clinicians and to promote high index of suspicion for early diagnosis and thereby timely management of various forms of cardiovascular tuberculosis.

Methods: Literature search for published evidence on cardiovascular complications of tuberculosis was conducted on MEDLINE, and Cochrane collaboration and the Cochrane Register of Controlled Trials (inclusive from 1980-2017). We used the following search terms: disseminated tuberculosis, tuberculous pericarditis, intracardiac tuberculoma, tuberculous endocarditis, myocardial tuberculosis, tuberculosis of blood vessels, and Takayasu arteritis.

Results and Discussion: The spectrum of cardiovascular complications of tuberculosis include pericarditis, myocardial involvement, intracardiac tuberculoma, and involvement of the blood vessels including coronary arteries with various manifestations ranging from no symptoms to sudden cardiac death.

Conclusion: Although tuberculosis can involve the heart and the blood vessels including coronaries, the diagnosis of cardiovascular tuberculosis remains challenging without high index of suspicion. The treatment of cardiovascular tuberculosis is primarily antituberculous chemotherapy and surgical intervention is rarely required. There is no robust evidence as to the potential association between TB and TA.

Key words: Tuberculosis, pericarditis, myocarditis, intracardiac tuberculoma, endocarditis, Takayasu arteritis

INTRODUCTION

Tuberculosis (TB) has existed for millennia and remains a major global public health problem particularly in developing countries. It is the ninth leading cause of death worldwide from a single infectious agent, ranking it rank above the Human Immunodeficiency Virus/Acquired Immunodeficiency Syndrome (HIV/AIDS) epidemic (1). The burden of TB has been adversely influenced by the human immunodeficiency virus epidemic and by social and economic factors that affect health care delivery which in turn made certain segments of the population particularly children very much affected (2).

Sub-Saharan Africa remains the epicenter of the HIV-epidemic and majority of the countries with the highest burden of TB are in this same region. It appears that there is intersection of triple epidemics in Africa: HIV/AIDS, TB and cardiovascular diseases (1,3). Cardiac manifestations of infectious diseases including HIV and TB are not given enough attention in clinical practice in developing countries.

However, studies show that HIV, TB and parasitic infections may produce a wide spectrum of cardiovascular manifestations including pericarditis, myocarditis, cardiomyopathy, pulmonary hypertension and rhythm abnormalities (3,4).

Tuberculosis is capable of infecting every organ in the body, and the heart is no exception. Cardiovascular involvement of TB occurs in the form of extrapulmonary (disseminated) TB and the diagnosis is usually challenging unless there is a high index of suspicion. Recent studies suggest that latent TB infection is associated with chronic inflammation that may lead to cardiovascular disease and intra cardiac structures or peripheral blood vessels, including coronaries can be involved in the disease process (5). Suggested mechanisms of cardiovascular disease in TB include direct effect on the myocardium and coronary arteries (TB arteritis), increased expression of pro-inflammatory cytokines and autoimmunity mediated by antibodies against mycobacterial heat stroke protein (HSP65) (5).

Cardiovascular involvement in patients with pulmonary TB occurs in about 2% of cases and it mainly affects the pericardium.

¹ Division of Pediatric Cardiology, Cardiac - Center Ethiopia, Addis Ababa

*Corresponding author E-mail: admengistu2000@yahoo.com

However, in rare instances the myocardium, the endocardium and the coronaries can be affected (6). There is paucity of published data addressing cardiovascular complications of TB and there is also a knowledge gap about this clinical issue among health professionals particularly in resource poor settings, where diagnostic tests are limited. The main goal of this review research work is hence to restore awareness among clinicians and to promote high index of suspicion for early diagnosis, thereby timely management of various forms of cardiovascular tuberculosis.

PATIENTS AND METHODS

Literature search for published evidence on cardiovascular complications of TB was conducted on MEDLINE, and Cochrane collaboration and the Cochrane Register of Controlled Trials (from 1980-2017, inclusive) using the following search terms: Disseminated tuberculosis, tuberculous pericarditis, intracardiac tuberculoma, tuberculous endocarditis, myocardial TB, tuberculosis of blood vessels, Takayasu arteritis. Additional relevant articles were retrieved from bibliographies. Eligibility criteria included randomized clinical trials, observational cohort studies (retrospective and prospective), case control studies and case reports that had been published in English language.

The selected outcome measures were potential cardiovascular complications of tuberculosis including TB pericarditis, intracardiac tuberculomas, TB endocarditis, myocardial tuberculosis, rhythm abnormalities related to TB involvement, TB of aorta and other blood vessels.

We assessed use of an appropriate source population, measurement methods of exposure and outcome, methods to deal with design specific issues such as bias and lost to follow up in selected reports. We did data extraction, synthesis and write up using the preferred reporting items for systematic review and meta-analysis (PRISMA) statement approach (7).

RESULTS

Fifty one study reports were identified through the electronic database searching. After removal of duplicates 47 remained. Of these, 10 reports were discarded because after reviewing the abstracts it was found that these reports did not fulfil the inclusion criteria or full text of the study was not available in English language. Finally, 37 studies met the eligibility (inclusion) criteria and were included in the systematic review (Figure 1).

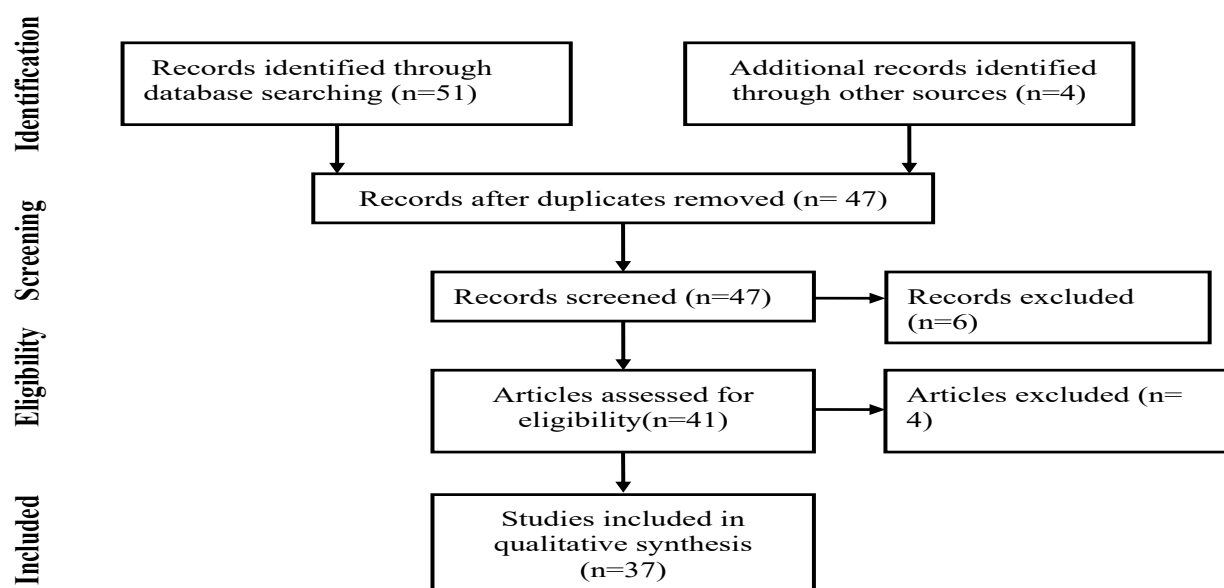


Figure 1: Flow diagram showing the different phases of literature search for the systematic review (PRISMA flow diagram)

DISCUSSION

Infections including TB do contribute to the development of cardiovascular disease mainly in developing countries. Tuberculosis is one of the oldest infectious diseases known to affect every organ and tissue of the human body including the heart. As part of disseminated form of the disease, TB can affect any part of the heart and the blood vessels including the coronaries.

Tuberculous Pericarditis: A series of studies on acute and subacute pericardial disease in the developed world, diagnosed in about 4% of patients, and in around 7% of patients with cardiac tamponade (8). However, in Africa TB pericarditis is by far the most common cause of pericardial disease in HIV-infected individuals, creating a dual challenge to the health care system (8,9). Studies show that the incidence of TB pericarditis in sub-Saharan Africa is increasing as a result of human immunodeficiency virus (HIV) epidemic. For instance, in the Western Cape, South Africa, one half of patients presenting with large tuberculous pericardial effusion had HIV infection (7). Cegielski, et al. reported a similar finding from Tanzania (9). Hence, in areas with a high prevalence of TB and HIV infection, a pericardial effusion is often considered tuberculous in origin unless an obvious alternative cause is identified.

Pericardial involvement of TB usually develops by retrograde lymphatic spread of *M. tuberculosis* from peritracheal, peribronchial, or mediastinal lymph nodes, or by hematogenous spread from primary TB infection. The immune response to viable acid-fast bacilli penetrating the pericardium is responsible for the morbidity associated with TB pericarditis and the disease process is insidious, presenting with non specific symptoms consisting of fever, malaise, dyspnea, night sweats and weight loss (5,8). Clinical presentation of TB pericarditis is in the form of pericardial effusion (80% of cases), effusive-constrictive pericarditis (15%), or constrictive pericarditis (5%) (10). Clinical evidence of pulmonary tuberculosis may be absent or subtle which is one of the main reasons why the diagnosis of TB pericarditis has been notoriously difficult and usually delayed.

Tuberculous pericarditis has a variable clinical presentation and should be considered in the evaluation of all cases of pericarditis, particularly in areas where the disease is endemic. In African patients with tuberculous pericardial effusion, evidence of chronic cardiac compression mimicking heart failure is the most common presentation, and 10% present with cardiac tamponade (8,10).

The diagnosis of pericardial effusion is generally performed by echocardiography, which also allows the quantitative assessment of the pericardial effusion and its hemodynamic effects. Although it is not specific for a tuberculous pathogenesis, echocardiographic findings of effusion with fibrinous strands on the visceral pericardium strongly suggest tuberculous pericardial effusion (11,12).

Mayosi, et al. proposed a diagnostic criteria for tuberculous pericarditis for countries and communities in which TB is a public health problem. Accordingly, a “definite” diagnosis of TB pericarditis is based on the demonstration of tubercle bacilli in pericardial fluid or on histological section of the pericardium. A “probable” diagnosis is made when there is proof of TB elsewhere in a patient with unexplained pericarditis, lymphocytic pericardial exudate with elevated adenosine deaminase (ADA) levels, and/or a good response to anti-TB therapy (8). In tuberculosis endemic areas, once there is a strong clinical suspicion of tuberculous pericarditis using the mentioned criteria as a guide, anti TB treatment needs to be started before a bacteriological diagnosis is established. Because anti-TB chemotherapy is known to increase survival dramatically in patients with tuberculous pericarditis (8,13). The approach to antituberculous therapy for tuberculous pericarditis is generally the same as that for pulmonary tuberculosis. However, the drug regimen may vary if there is underlying HIV infection or if the patient has drug-resistant TB.

The task force for the diagnosis and management of pericardial diseases of the European Society of Cardiology recommends treating cardiac tamponade by drainage of the pericardial fluid, preferably by needle pericardiocentesis with the use of echocardiographic or fluoroscopic guidance, and performing it without delay in unstable patients (13). Although open drainage appears to abolish the need for repeat pericardiocentesis, it was not found to significantly influence the need for pericardiectomy for subsequent constriction. Hence, routine open drainage of massive tuberculous pericardial effusion by substernal pericardiectomy is not recommended (10).

In addition to pericardial effusion, other potential complications of TB pericarditis include constrictive pericarditis and effusive constrictive pericarditis, which are the most serious sequelae of TB pericarditis occurring in 30-60% of patients, despite prompt anti-TB therapy and the use of corticosteroids. TB is the commonest cause of constrictive pericarditis in Africa and Asia with variable presentations, ranging from asymptomatic to severe constriction leading to significant hemodynamic consequences (10,13).

Echocardiography is a non-invasive tool in confirming the diagnosis of subacute constrictive pericarditis, which typically shows thick fibrinous exudates in the pericardial sac, normal sized cardiac chambers, absence of valvular heart disease and absence of myocardial hypertrophy. Differentiation of constrictive pericarditis from restrictive cardiomyopathy by echocardiography is a challenging task due to their complex hemodynamics (14). Because the former is potentially curable unlike the latter, a clinical condition where its treatment is limited, reasonable differentiation of the two conditions is critical. The Mayo clinic echocardiographic criteria for the diagnosis of constrictive pericarditis, which has 87% sensitivity and 97% specificity, is currently the widely accepted approach. In this criteria, the authors reported that, respiration-related ventricular septal shift, preserve or increased medial mitral annular e' velocity and prominent hepatic vein expiratory diastolic flow reversals are independently associated with the diagnosis of constrictive pericarditis (15).

The treatment of tuberculous pericardial constriction involves the use of anti-TB chemotherapy for six months. Pericardiectomy is recommended if there is no improvement or deterioration in the clinical condition of the patient after 4 to 8 weeks of anti-tuberculosis drug therapy (8,10,13). Three decades ago, Bashi and colleagues (16) reported from India early and long-term results of partial pericardiectomy in 72 confirmed cases of tuberculous constrictive pericarditis with good hemodynamic and clinical outcomes. However, Geske, et al. in their comprehensive review, recently reported better outcomes following complete pericardiectomy compared with partial pericardiectomy or pericardial window in terms of lower perioperative mortality, less postoperative cardiac output syndrome, shorter hospital stay, and improved long term survival (12). The task force for the diagnosis and management of pericardial diseases of the European Society of Cardiology also recommends removing as much of the pericardium as possible with all constricting parietal and epicardial layers using a sternotomy approach as left anterolateral thoracotomy permits only a partial resection (13).

The clinical management of effusive form of tuberculous constrictive pericarditis is challenging, because pericardiocentesis does not relieve the impaired filling of the heart and surgical removal of the fibrinous exudates coating the visceral pericardium is not possible. In such patients, anti-tuberculosis drugs should be given and patients monitored clinically and by echocardiography for development of constrictive pericarditis (10,13).

Myocardial tuberculosis: Myocardial involvement of tuberculosis is uncommon and is described in up to 0.35% of patients dying from tuberculosis (17). Three distinct pathologic varieties have been reported that include nodular, miliary and diffuse infiltrative types among which the first is the most common. The modes of spread of TB to the myocardium are through mediastinal lymph nodes, direct invasion from the pericardium, or via hematogenous spread (17-19).

Tuberculous myocarditis is unusual form of cardiovascular tuberculosis, which is usually asymptomatic but it may present with rhythm disturbances, congestive heart failure and ventricular aneurysms (19). In a report of 19 patients with cardiac TB, myocardial involvement was diagnosed ante mortem in only one patient suggesting that diagnosis of myocardial TB is challenging and requires a high index of suspicion in the appropriate clinical setting. In the same study, left ventricular aneurysm was noticed in three patients (20). Michira et al in their systematic review of cases with TB myocarditis reported concomitant pulmonary TB and pericardial involvement in nearly half of the cases (18).

Sudden cardiac death had been reported as a complication of myocardial TB probably due to ventricular arrhythmias, suggesting that this form of cardiac TB should be considered in the differential diagnosis when cardiac rhythm disturbances occur in a patient with structurally normal heart particularly with evidence of involvement of TB in other organs (22). Myocardial TB presented with heart failure and dilated cardiomyopathy confirmed by endomyocardial biopsy had also been reported from India suggesting that TB might be one of potential causes of dilated cardiomyopathy which is curable by anti-tuberculosis chemotherapy (21).

Endocardial involvement and Intracardiac tuberculoma: Endocardial TB is rarely reported in the literature with occurrence of 0.14% in one large autopsy series (20). Clinical presentation of intracardiac tuberculomas depends on the site of the mass lesion and includes pulmonary vein obstruction caused by left atrial mass lesions, right ventricular outflow tract obstruction, superior vena cava obstruction, aortic insufficiency and arrhythmias. Chang and associates reported military TB with intracardiac tuberculoma in the right atrium and superior vena cava that presented with nonspecific symptoms and atrial tachycardia in a pediatric patient that was successfully treated with surgical excision of the mass lesion and anti-tuberculous chemotherapy (23).

Cardiac tuberculomas infiltrating all cardiac layers, in the form of obstructive mass lesion in the vena cavae, and within cardiac chambers have been described in the literature in all age groups, ranging from an 11-year old child to a 43-year old man (24-27). Although the first report of tuberculous endocarditis dates back to more than a century ago, its true incidence is unknown, partly because most early cases were diagnosed on autopsy. A very extensive review on TB endocarditis by Lie, et al. revealed that endocardial involvement of TB usually occurs in patients with military TB (28). However, TB endocarditis that caused destruction of aortic valve with severe regurgitation that required valve replacement was reported in an immunocompetent host without underlying military TB (29). Authors of this study also suggested the Dukes criteria that is currently widely used for the diagnosis of infective endocarditis to include evidence of TB, which appears to be reasonable, particularly in areas where TB is a common clinical problem.

Endocardial TB may also present with sustained life threatening ventricular tachycardia that responds well to the conventional anti-tuberculous therapy (30). In spite of the fact that cardiac tuberculomas and TB endocarditis are rare, they should be suspected in patients with arrhythmias or intracardiac mass lesion who have been exposed to TB or has evidences of disseminated TB elsewhere in the body. Like other forms of cardiac TB, the primary treatment of intracardiac tuberculomas or TB endocarditis is anti-tuberculous medication. However, if the diagnosis remains unclear or in cases of severe hemodynamic compromise, refractory arrhythmias, the surgical resection of tuberculomas or valve replacement may be considered (23,25).

TB of coronaries, aorta and peripheral blood vessels: A large nationwide population based retrospective cohort study conducted in Taiwan revealed that TB patients are at higher risk of developing acute coronary syndrome (ACS) after adjusting for important co-morbidities. As to the possible mechanisms, the authors of this study proposed that *M. tuberculosis* results in chronic granulomatous inflammation, which may be associated with coronary TB (31). Huaman, et al. also proposed an increase inflammation leading to coronary artery plaque formation and/or plaque rupture and autoimmunity mediated by antibodies against mycobacterial HSP65 as possible mechanism of the effect of TB infection on cardiovascular disease (5). Sudden death due to tuberculous coronary artery occlusion diagnosed on autopsy has been reported in the literature (33), suggesting that even isolated coronary artery involvement can occur.

Tuberculous aortic aneurysms are well described in the literature, the first being in 1882. Canaud and associates reported three cases of mycotic aneurysm secondary to TB infection of the aorta with favorable outcomes in all cases being treated with a combination of surgical aortic replacement and anti-tuberculous chemotherapy for nine months which is unlike the current conventional recommendation of duration of anti-tuberculous treatment (32).

TB can also involve the renal arteries leading to renovascular hypertension (34). Interestingly, a nationwide population-based study showed that the risk for peripheral arterial disease was nearly four times higher in patients with TB compared with individuals without the disease after adjusting for age, sex, co-morbidities and socioeconomic status (35). Although more research is required to elucidate the association between TB and peripheral arterial disease, considering TB when evaluating a patients risk of developing peripheral arterial diseases might be of help, particularly in areas where TB is endemic.

There had been published reports that suggested association between TB and Takayasu's arteritis (TA) (5,36,37). Takayasu's arteritis is a chronic vasculitis of unknown origin that primarily affects the aorta and its main branches. Pantel et al reported the prevalence of active TB that ranged from 21.8% to 70% in patients with TA. The authors of the same study also showed that patients with TA were 46.6 times more likely to have had active TB compared with the general population in India where both clinical conditions are commonly encountered (35).

This review research work is not without limitations. First, the study is based on generally small scale, cross-sectional, retrospective studies and case reports that somewhat might limit its quality for generalizability. Second, biases present in the original articles cannot be totally eliminated and thirdly despite the attempt of conducting an extensive search for articles with sound methodology, there was still a possibility of missing relevant articles, for instance, because of the restriction to literatures reported in English language.

Conclusion and implications: Although TB can involve the heart and the blood vessels including coronaries, the diagnosis of cardiovascular TB remains challenging without high index of suspicion. It should be suspected in patients with intracardiac mass lesion, heart failure and arrhythmias who have structurally normal heart and associated disseminated TB elsewhere in the body particularly in individuals with underlying immunodeficiency states.

The treatment of cardiovascular TB primarily anti-tuberculous chemotherapy and surgical intervention is rarely required. However, the exact duration of therapy with anti-tuberculous drugs in cardiovascular TB remains unclear.

Further research is required to elucidate the association between TB and Takayasu arteritis.

REFERENCES

1. Global tuberculosis report 2017. Geneva: World Health Organization; 2017. Licence: CC BY-NC-SA 3.0 IGO.
2. Swaminathan S, Rekha B. Pediatric Tuberculosis: Global Overview and Challenges. *Clinical Infectious Diseases* 2010;50(S3):S184–S194.
3. Mengistu AD. The Emerging Concern of Cardiovascular Complications in Children with Human Immunodeficiency Virus Infection in Sub-Saharan Africa: A Systematic Review. *ARC Journal of AIDS* 2017; 2(2):20–28.
4. Mocumbi AH, Ferreira MB. Neglected Cardiovascular Diseases in Africa. *J Am Coll Cardiol* 2010;55(7):680–7.
5. Human MA, Henson D, Eduardo Ticona E, et al. Tuberculosis and cardiovascular disease: linking the epidemics. *Travel Medicine and Vaccines* 2015; 1:10DOI 10.1186/s40794-015-0014-5.
6. Rajesh S, Sricharan KN, Jayaprakash K, Francis N, Monteiro P. Cardiac involvement in patients with pulmonary tuberculosis. *Journal of Clinical and Diagnostic Research* 2011 ;5(3):440-442.
7. Liberti A, Altman DG, Tetzlaff J, et al. PRISMA statement for reporting systematic reviews and meta-analyses of studies that evaluate health care interventions: explanation and elaboration. *Br Med J* 2009; 339:b2700
8. Mayosi BM, Burgess LJ, Doubell AF. Tuberculous Pericarditis. *Circulation* 2005;112:3608-3616.
9. Cegielski JP, Lwakatare J, Dukes CS, et al. Tuberculous pericarditis in Tanzanian patients with and without HIV infection. *Int J Tuberc Lung Dis* 1994;75(6):429-34
10. Syed FF, Mayosi BM. Pericardial disease: an evidence-based approach to clinical management. In: Yusuf S, Cairns JA, Camm AJ, Fallen EL, Gersh BJ (Editors). *Evidence-Based Cardiology*, Wiley Blackwell, BMJ books, 3rd edition, 2010; pp:850-853.
11. Imazio M, Adler Y. Management of pericardial effusion. *European Heart Journal*;2013;34,1186–1197.
12. Cherian G. Diagnosis of tuberculous aetiology in pericardial effusions. *Postgrad Med J* 2004;80:262–266.
13. Adler Y, Charron P, Massimo Imazio M, et al. Task Force on the Diagnosis and Management of Pericardial Diseases of the European Society of Cardiology. Guidelines on the diagnosis and management of pericardial diseases. *European Heart Journal*;2015;36:2921–2964.
14. Geske JB, Anavekar NS, Rick A, Nishimura RA, Oh JK, Gersh BJ. Differentiation of Constriction and Restriction. *J Am Coll Cardiol* 2016;68:2329–47.
15. Welch TD. Echocardiographic Diagnosis of Constrictive Pericarditis: Mayo Clinic Criteria. *Circ Cardiovasc Imaging* 2014;xx:1-35
16. Bashi VV, John S, Ravikumar E, et al. Early and late results of pericardiectomy in 118 cases of constrictive pericarditis. *Thorax* 1988;43:637-641.
17. Gulati GS, Kothari SS. Diffuse infiltrative cardiac tuberculosis. *Annals of Pediatric Cardiology* 201;(4)1:87-89.
18. Michira BN, Alkizim FO, Matheka DM. Patterns and clinical manifestations of tuberculous myocarditis: a systematic review of cases. *Pan Afr Med J* 2015;21:118.
19. Behr G, Palin HC, Temperley JM. Myocardial tuberculosis. *Br Med J*;1977;95xx-xx
20. Rose AG. Cardiac tuberculosis. A study of 19 patients. *Arch Pathol Lab Med* 1987;111(5): 422-6,
21. Agarwal R, Malhotra P, Awasthi A, Kakkar N, Gupta D. Tuberculous dilated cardiomyopathy: an under-recognized entity? *BMC Infectious Diseases* 2005;5:29-XX
22. Liu A. Sudden cardiac death and tuberculosis- How much do we know? *Tuberculosis* 2012;92(4): 307-313
23. Chang B, Ha J, Kim J, Chung N, Cho S. Intracardiac Tuberculoma. *Ann Thorac Surg* 1999;67:228–31.
24. Jeilan M, Schmitt M, McCann G. Cardiac Tuberculoma. *Circulation*; 2008;117:984-986.
25. Cantinotti M, De Gaudio M, de Martino M, et al. Intracardiac left atrial tuberculoma in an eleven-month-old infant: case report. *BMC Infectious Diseases* 2011;11:359-XX
26. Monga A, Arora A, Makar RP, Gupta A. A rare site for tuberculosis. *Can Med Ass J* 2002;167(10):1149-1150.
27. Al-Nasser I, Anwar AM, Nosir Y, et al. Bicaval obstruction complicating right atrial tuberculoma: the diagnostic value of Cardiovascular MR. *Journal of Cardiovascular Magnetic Resonance* 2008;10:60-xx
28. Liu A, Nicol E, Hu Y, Coates A. Tuberculous endocarditis. *Int J Cardiol* 2013;167(3): 640-645.

29. Abrara A, Newsholme W, Klein JL, Chambers JB. Tuberculous endocarditis in an immunocompetent host without military tuberculosis. *Int J Tuber Lung Dis* 2014;XX:1047-1048.
30. O'Neill PG, Rokey H, Greenberg S, Pacifico A. Resolution of Ventricular Tachycardia and Endocardial Tuberculoma following Antituberculosis Therapy. *Chest* 1991;100:1467-69.
31. Chung WS, Lin CL, Hung CT, et al. Tuberculosis increases the subsequent risk of acute coronary syndrome: a nationwide population-based cohort study. *Int J Tuberc Lung Dis* 2014;18(1):79-83.
32. Anaud L, Marzelle J, Bassinet L, et al. Tuberculous aneurysms of the abdominal aorta. *J Vasc Surg* 2008;48:1012-6.
33. Peddle L, Otto M. Coronary artery tuberculosis: An unusual case of sudden death. *Legal Medicine* 2018;30: 56–58.
34. Bouuziane Z, Boukhabrine K, Lahlou Z, et al. Tuberculosis of the renal artery: a rare cause of renovascular hypertension. *Ann Vasc Surg* 2009;23(6):786.e7-9.
35. Wang SH, Chien WC, Chung CH, et al. Tuberculosis increases the risk of peripheral arterial disease: A nationwide population-based study. *Respirology* 2017;22(8):1670-1676.
36. Pantel RH, Goodman BW. Takayasu Arteritis: The relationship with tuberculosis. *Pediatrics* 1981;67:84-88.
37. Aggarwal A, Chag M, Sinha N, Naik S. Takayasu's arteritis: role of *Mycobacterium tuberculosis* and its 65 kDa heat shock protein. *Int J Cardiol* 1996; 55:49–55.